

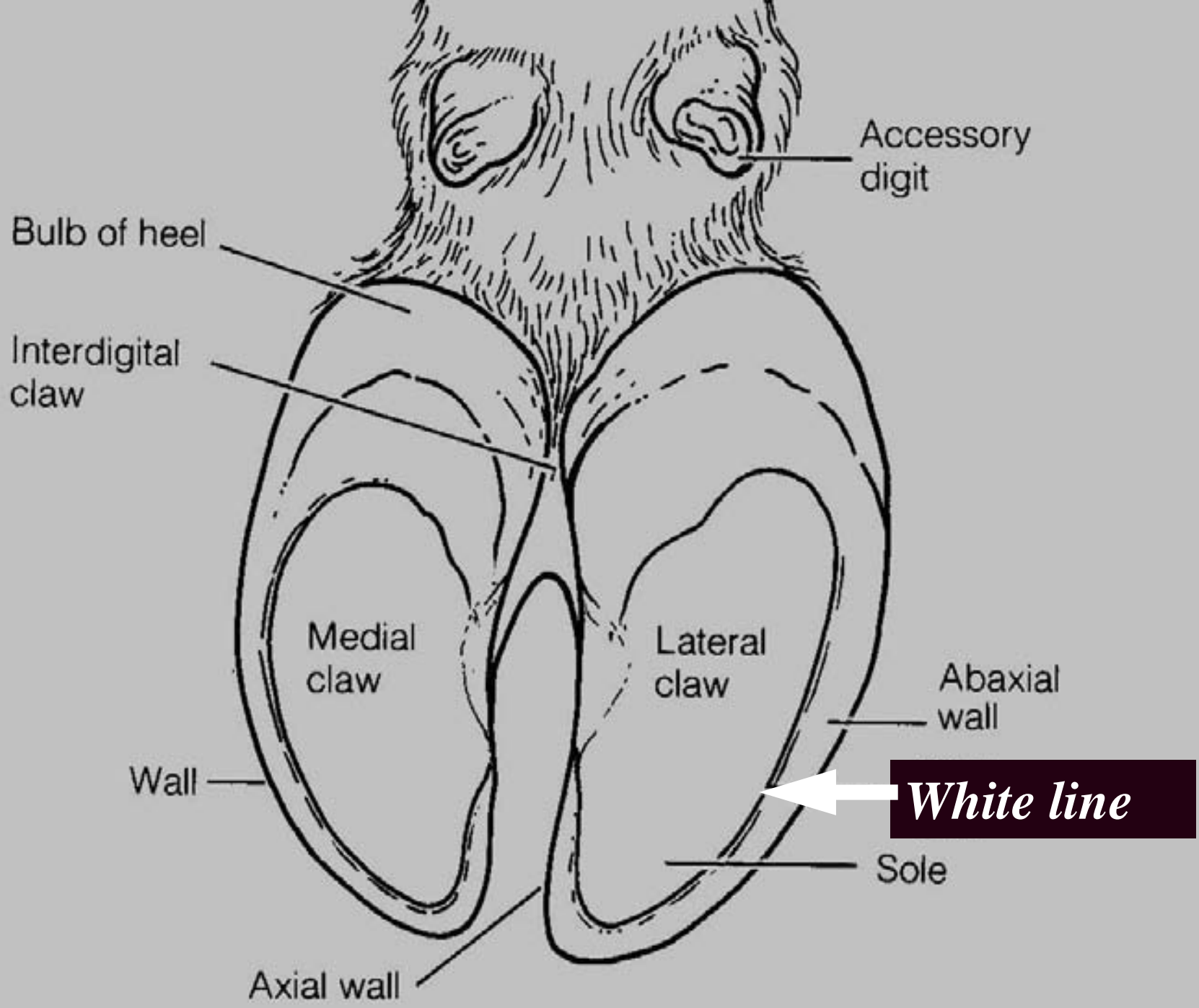
# White line disease

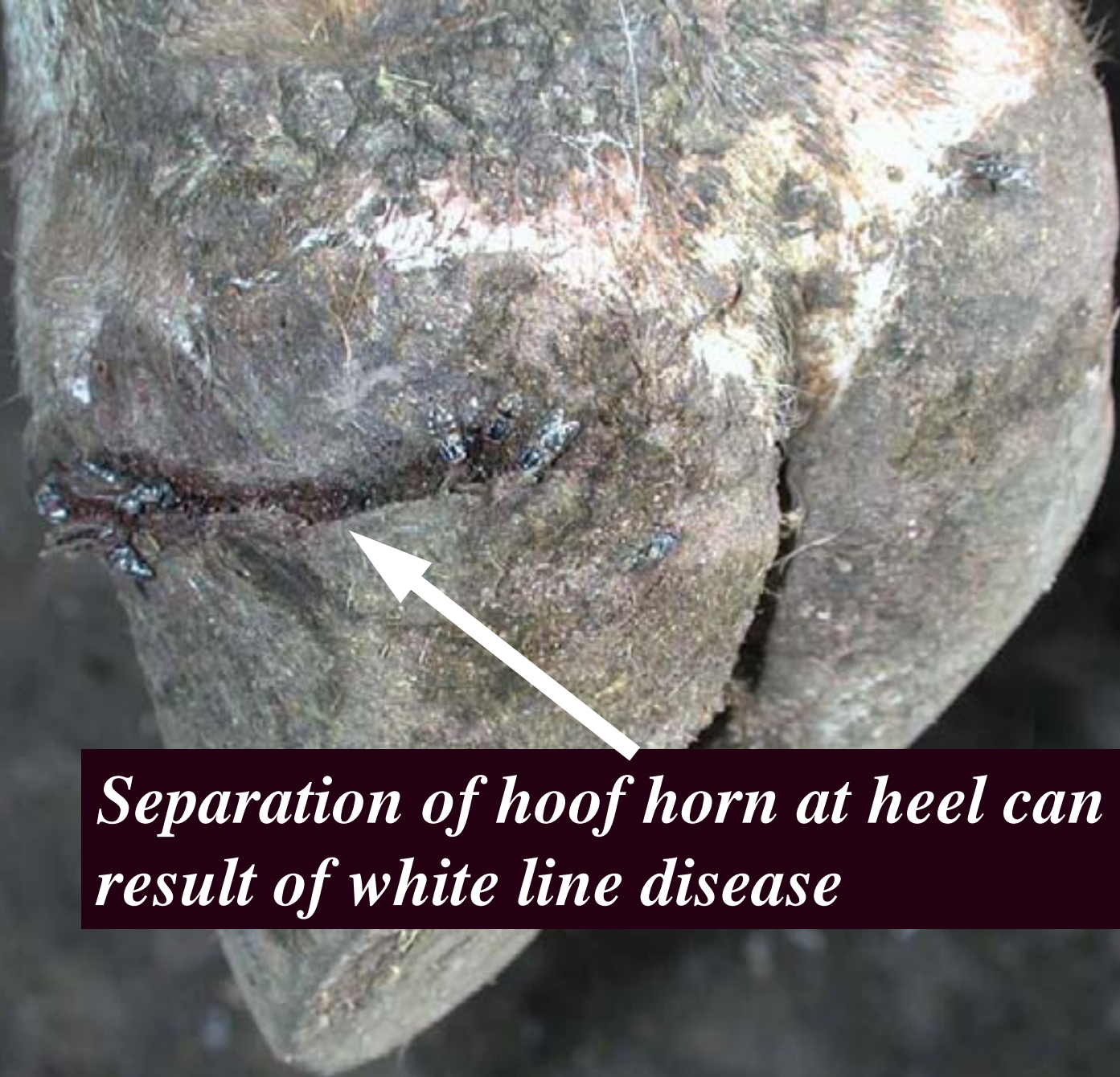



# What is the white line?

- The white line is the fibrous line between the wall and sole of the hoof
- The joint is weaker than either the wall or sole
- White line disease may be associated with subclinical laminitis or with cows twisting and turning on concrete

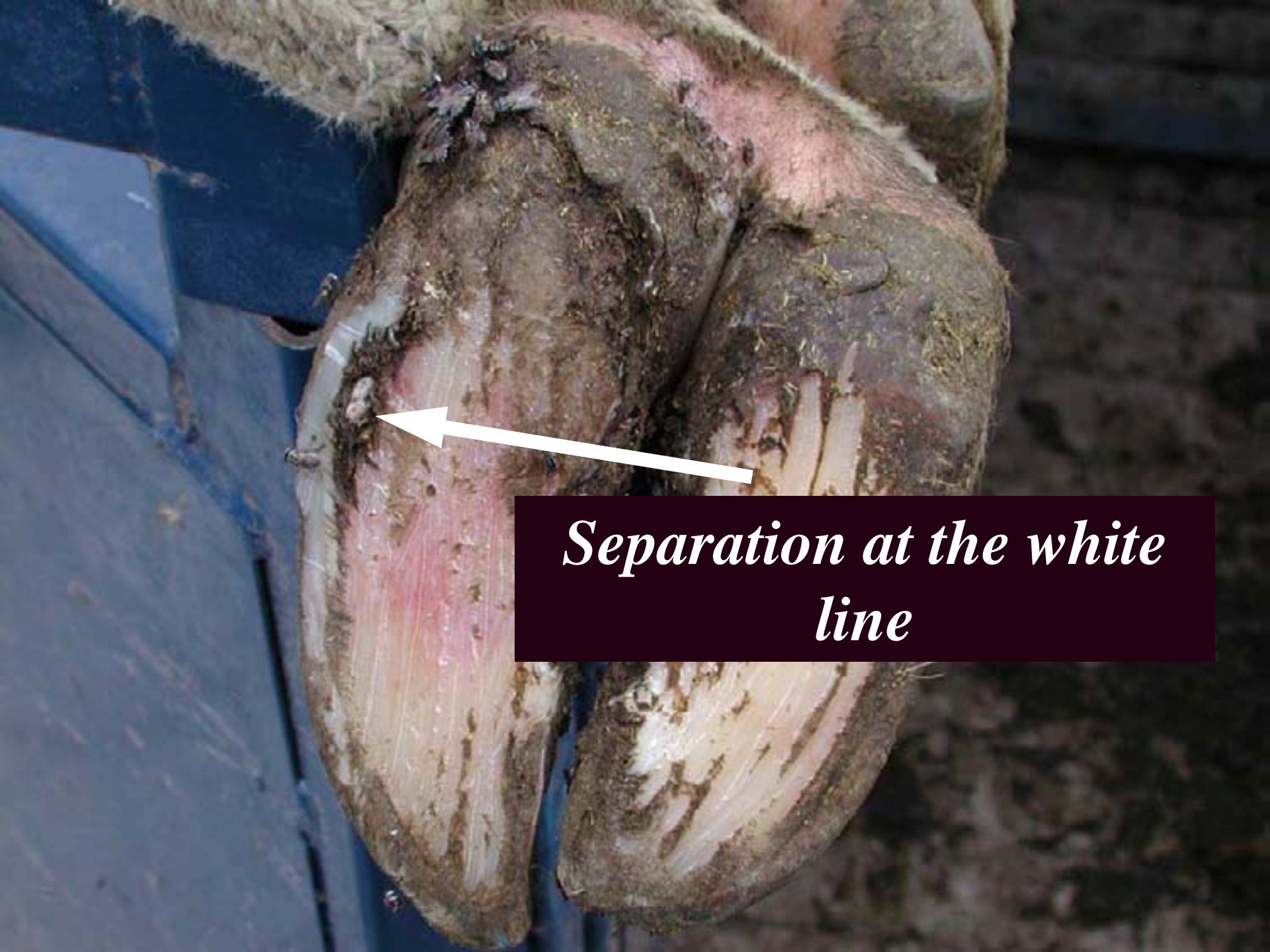



*Separation of hoof horn at heel can be a result of white line disease*







*Separation at the white  
line*





*Extensive white line separation*





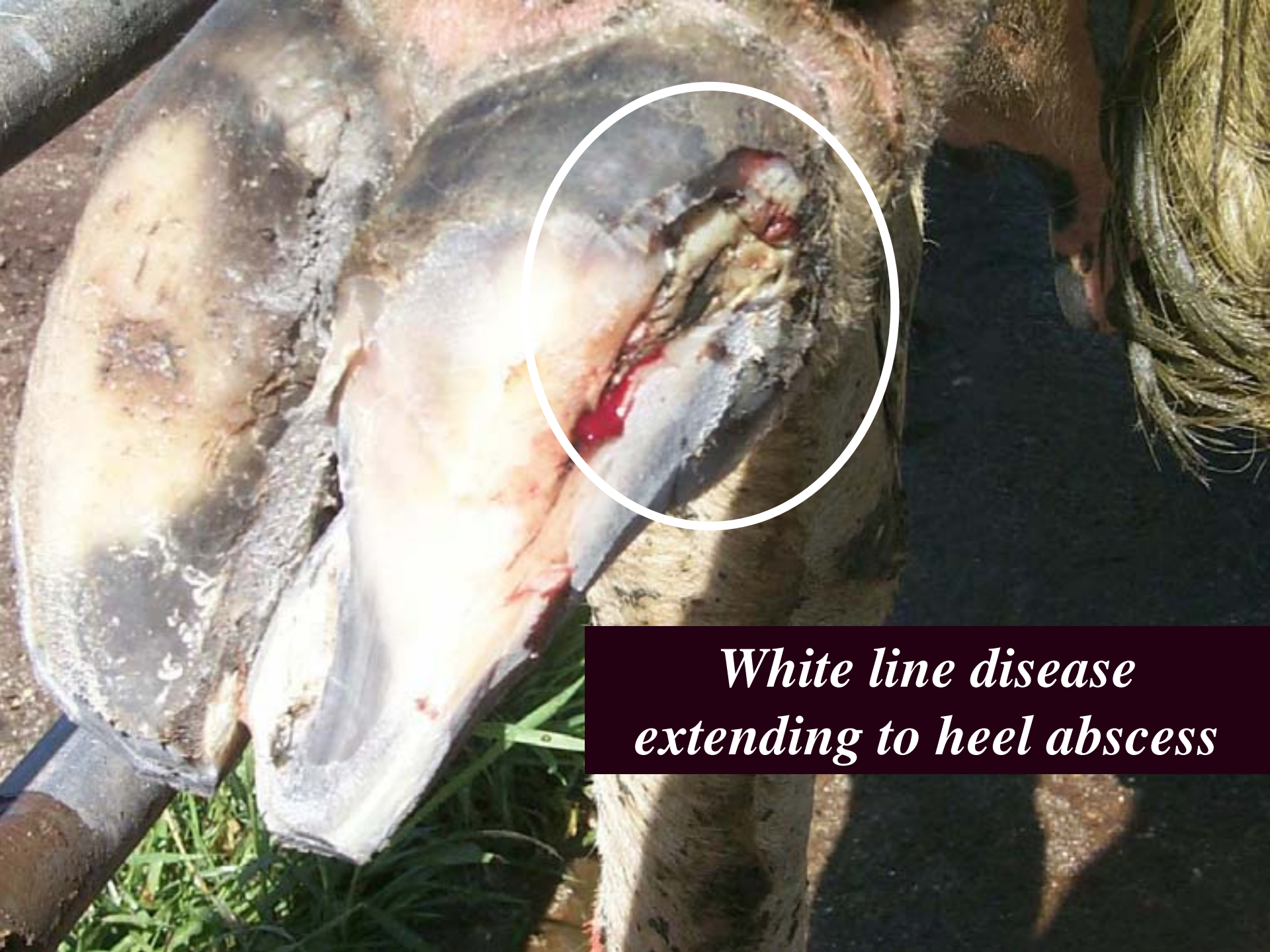





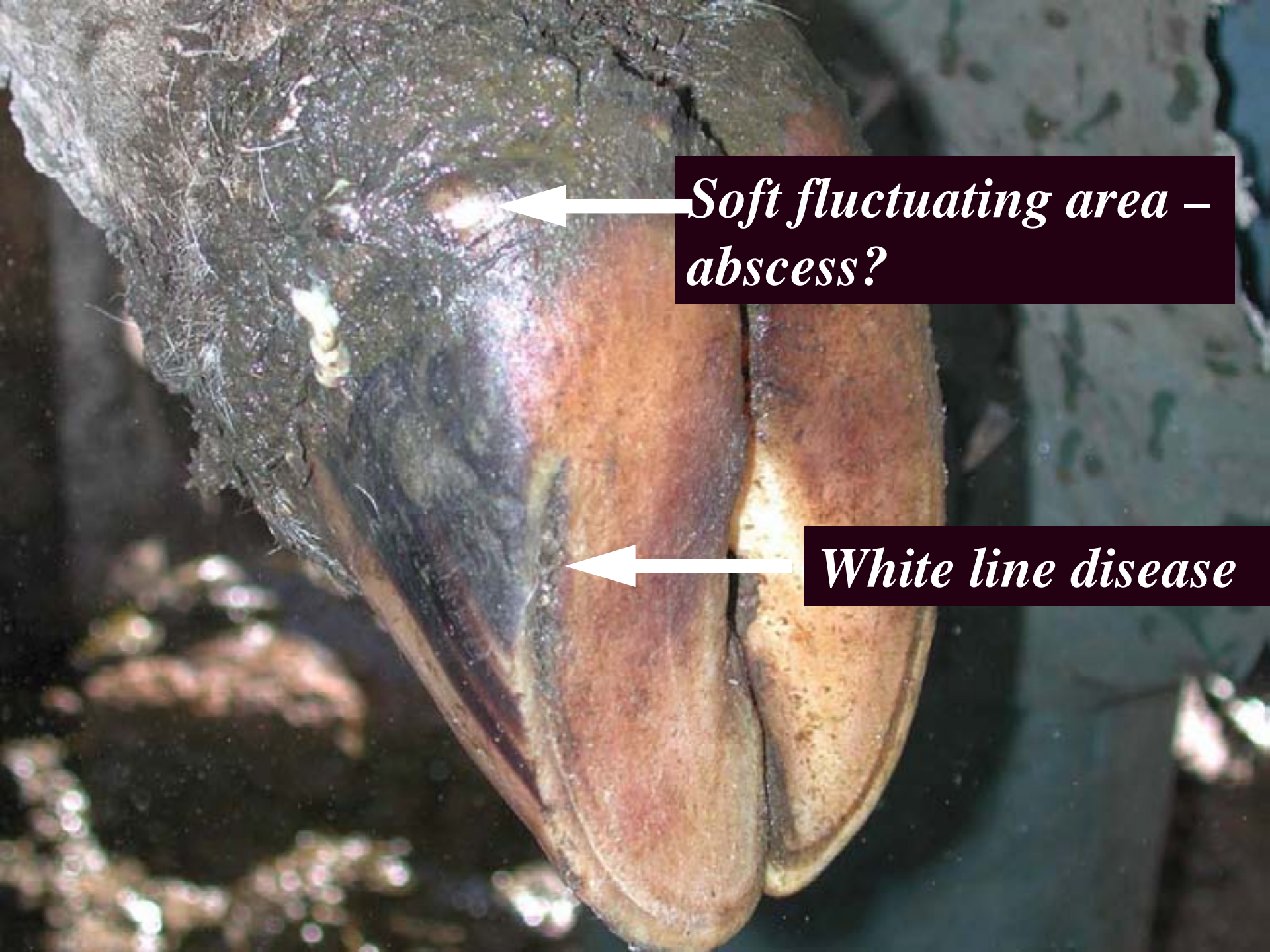






*White line disease  
extending to heel abscess*

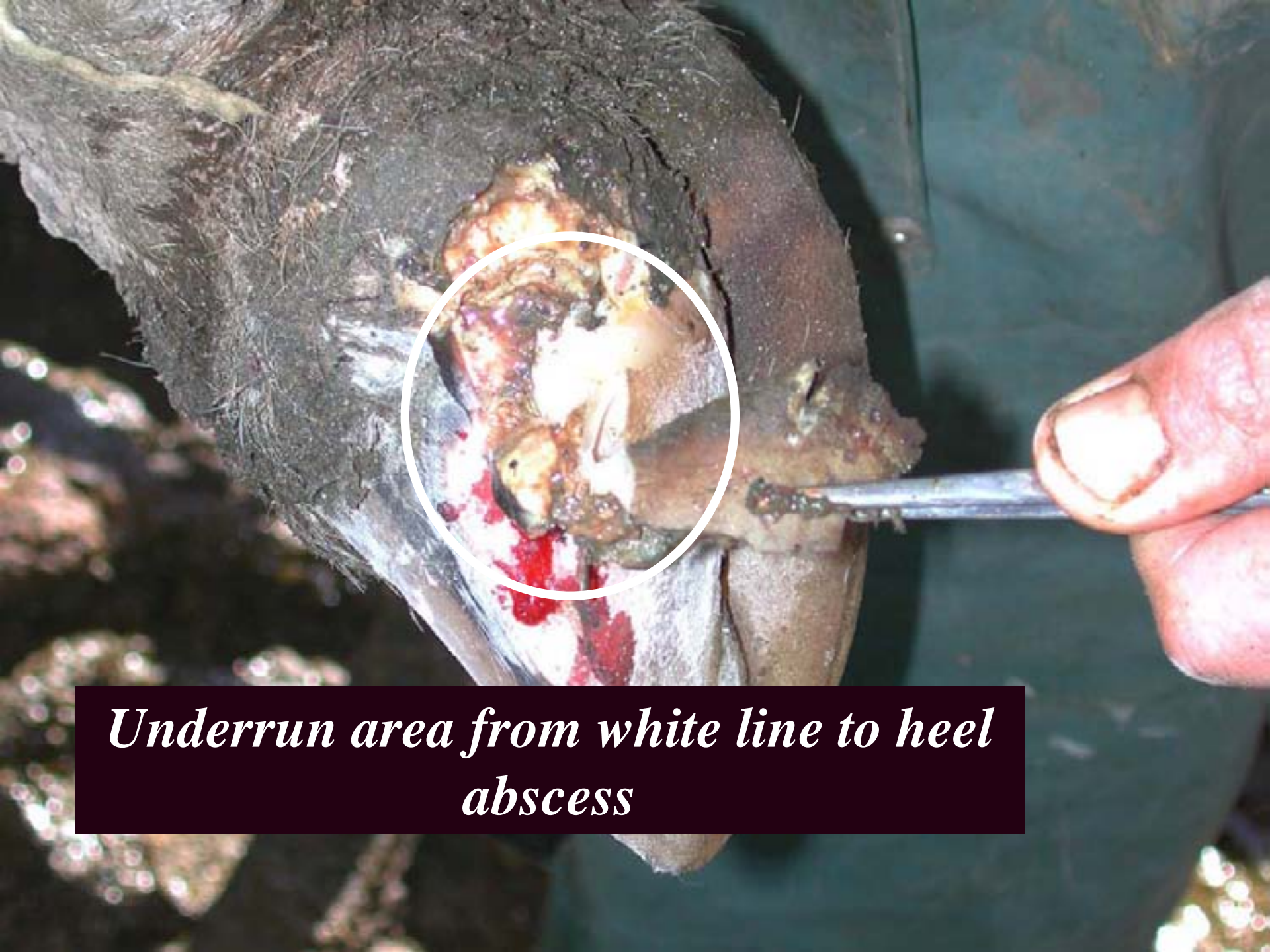



*Soft fluctuating area – abscess?*

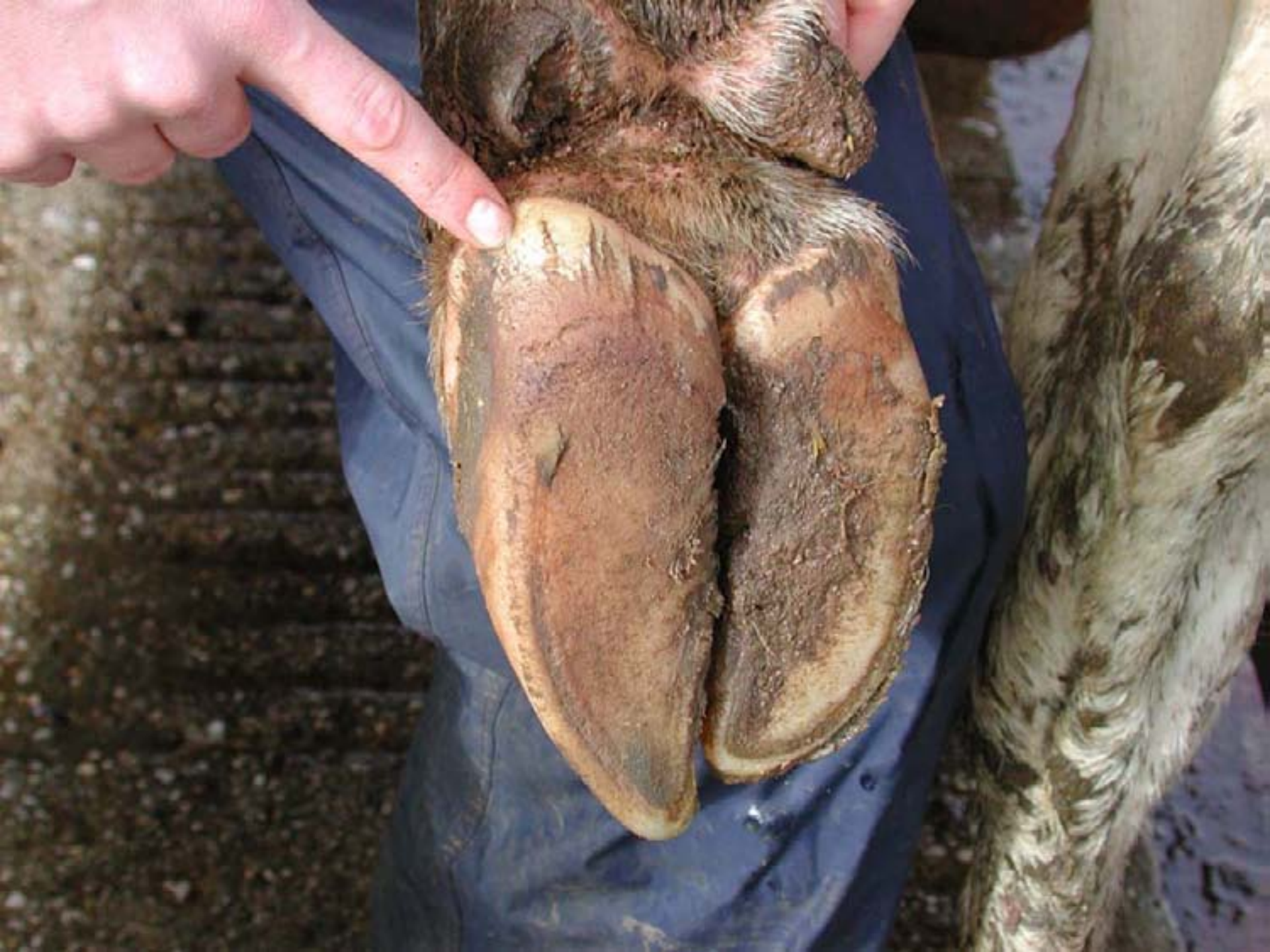*White line disease*





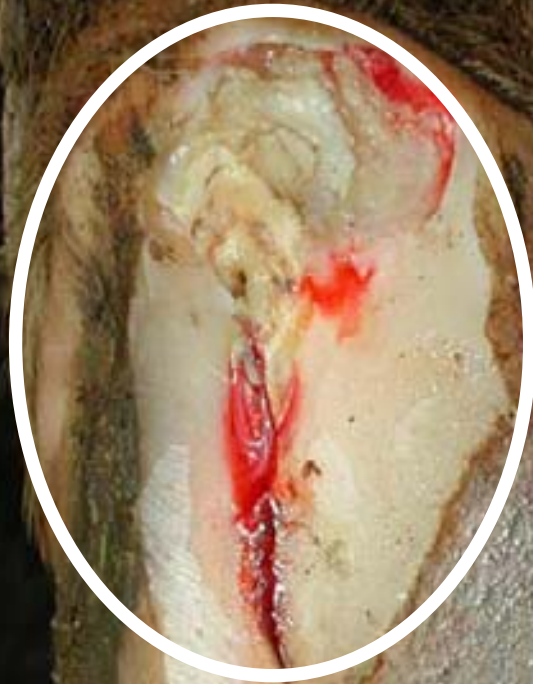*Underrun area from white line to heel  
abscess*







*Abscess extending from white line disease*





# Treatment of white line disease

- Pare away the defect so that sand and gravel do not pack into the pared area
- Where necessary, remove hoof wall of the defect to allow drainage
- In severe cases, apply Cowslip to unaffected claw and treated with antibiotics if necessary